



Submitted: 15.8.2016

Accepted: 27.10.2016

Conflict of interest

JD: Convatec, Coloplast, Mölnlycke, Urgo, Smith & Nephew. JGB: employee of B. Braun Melsungen AG. HB: employee of Coloplast GmbH. JH: employee of Smith & Nephew GmbH. PW: employee of URGO GmbH. KCM: Coloplast, Urgo, Smith & Nephew.

DOI: 10.1111/ddg.13233

Evidence for silver in wound care – meta-analysis of clinical studies from 2000–2015

**Joachim Dissemond¹,
 Johannes Georg Böttrich²,
 Horst Braunwarth³, Jörg Hilt⁴,
 Patricia Wilken⁵, Karl-Christian Münter⁶**

(1) Department of Dermatology, Venerology, and Allergology, University Hospital Essen, Essen, Germany

(2) B. Braun Melsungen AG, Melsungen, Germany

(3) Coloplast GmbH, Hamburg, Germany

(4) Smith & Nephew GmbH, Hamburg, Germany

(5) URGO GmbH, Sulzbach, Germany

(6) Joint Dermatology Practice Bramfeld, Hamburg, Germany

Summary

Background: Given that the scientific evidence for silver in wound care is generally considered insufficient, there is uncertainty among users regarding its clinical use.

Material and methods: A group of experts evaluated the clinical studies on silver in wound management published from 2000–2015.

Results: Overall, 851 articles were identified, 173 of which were included and categorized. There were 31 randomized controlled trials (RCTs) and eight cohort studies. Twenty-eight of these studies showed statistically significant outcome parameters in support of silver. While nine of these studies investigated burn injuries, 20 addressed other indications (venous leg ulcers: 9; pressure ulcers: 3; chronic wounds: 2; diabetic foot ulcer: 1; other types of wounds: 5). In 16 studies, the primary parameter was wound healing, whereas quality of life including pain was assessed in twelve studies; cost-effectiveness, in eight studies; reduction of bacterial load, in three studies. Based on these results, a treatment algorithm for the clinical use of silver in wound care has been developed.

Conclusions: The present meta-analysis shows that the evidence base for silver in wound management is significantly better than perceived in the current scientific debate. Thus, if used selectively and for a limited period of time, silver not only has antimicrobial effects but is also characterized by an improvement in quality of life and good cost-effectiveness.

Introduction

The use of silver in wound management has a very long tradition. In Egypt, the application of silver leaf for wounds was practiced as early as 1850 BC, and silver-coated vessels were used in ancient times for the storage of water and food to keep them from spoiling. While the antimicrobial effects of silver were known, they were not understood in greater detail. In his textbooks, Hippocrates, too, described the positive effects of silver on wound healing. At the end of the 19th century, many medications for the treatment of ocular diseases, skin disorders, and infectious diseases contained silver. In particular, Credé's prophylaxis, which was

Introduced in 1881 and continued for nearly a century, consisted of the instillation of silver nitrate 1 % solution into the eyes of newborns in an effort to prevent gonorrhoea. Around 1920, colloidal silver was approved for wound treatment by the US FDA (Food and Drug Administration). In 1968, silver sulfadiazine (SSD) was introduced into clinical practice, and – for some years – continued to be the gold standard in topical antimicrobial treatment, especially in the management of burn injuries [1].

Despite this very long tradition of silver in medical therapy, its scientific evidence has frequently been critically assessed, especially with respect to wound treatment. Searching for clinical studies published until 2009, the most recent

(2010) Cochrane meta-analysis of scientific data on silver in wound treatment found 26 randomized controlled trials (RCTs) with a total of 2,066 patients. The authors concluded that the evidence hitherto available was insufficient to determine whether silver-containing dressings promoted wound healing or prevented wound infections. It was pointed out, however, that the heterogeneity of the products as well as the parameters and results of the RCTs greatly limited the validity of the analysis [2]. Consequently, the evidence for silver-containing wound care agents, as for most therapeutic agents employed in wound treatment, has to date been considered insufficient [3]. While current guidelines do highlight the potential benefits of most wound care agents, it remains up to the individual experience of the treating physician as to when, how long, and in which patients these agents are to be used.

Recommendations in scientific medical guidelines are based on clinical evidence and/or expert consensus. The underlying scientific evidence is divided into categories that reflect the validity of the study type and the data obtained. However, with respect to infected wounds and those marked by bacterial colonization, these recommendations are insufficient for topical antimicrobial treatment in routine clinical practice [4]. The aim of the authors was therefore to review the scientific basis of wound treatment using silver, taking into account the numerous studies of recent years as the basis for a practical recommendation for its clinical use.

Material and methods

A group of experts conducted a structured search in the Pubmed, Embase, and Cochrane databases for the period from January 1, 2000 to June 30, 2015. The following search items were used: silver (all forms), wound, antimicrobial wound dressings, biofilm, wound healing, preclinical studies (in vitro and animal studies), health technology assessment (HTA), meta-analyses, reviews, randomized controlled trials (RCTs), clinical efficacy/tolerability studies including recommendation, guidelines, and best practice. This was supplemented by a manual search.

Articles without (direct) significance for the listed topics, such as chemotherapy, coated catheters and implants, as well as articles with antiseptic principles other than silver were excluded. Included were RCTs (evidence level 1b) and comparative studies (evidence level 2b individual cohort study) on silver.

In the context of this meta-analysis, the studies were not scientifically reevaluated as all studies included had been published in peer-reviewed journals following independent scientific reviews. The studies were classified by indications and study type, listed by topic, and categorized by endpoints. Separate statistical analysis was not performed.

Results

Overall, 851 articles were identified using the aforementioned search parameters. A subsequent review showed that 30 articles had been collected twice. Following a closer look at the abstracts of the remaining 821 articles, 157 articles were determined to be studies that met the inclusion criteria and warranted further analysis. These studies were broken down into the following categories (Figure 1) [5]:

- ▶ 34 review articles (systematic reviews, meta-analyses)
- ▶ 39 clinical studies (RCTs and comparative cohort studies)
- ▶ 32 case series or case studies
- ▶ 31 preclinical studies (in vitro studies, animal studies)
- ▶ 21 studies on biofilm

With respect to the primary objective of the present analysis, the 39 clinical studies were of particular interest. They included 31 RCTs and eight controlled cohort studies. Of these 39 clinical studies, 28 showed statistically significant outcome parameters in favor of silver (Tables 1–5). One study revealed a comparable reduction in wound pain and bacterial load for silver and polyhexanide (PHMB). While nine of these studies investigated burn injuries (including eight RCTs), 20 addressed other indications (9: venous leg ulcers; 3: pressure ulcers; 2: chronic wounds; 1: diabetic foot ulcer; and 5: other types of wounds). In 16 studies, the primary parameter was wound resolution (healing, wound closure, wound size/area reduction, completed re-epithelialization). Twelve studies examined quality of life including pain; eight, cost-effectiveness; and three, the reduction of bacterial load (bioburden) (Table 6).

Ten clinical studies (only) partly showed statistically significant outcome parameters in favor of silver (Table 7). In other clinical studies, other endpoints were partially supported the use of silver, such as surgical site infections (SSIs), reduction in wound size or resistance to silver (Table 8).

Discussion

In its elemental form, silver is nonreactive and has thus no antimicrobial effects. Silver atoms (Ag or Ag^0) only acquire such properties when they lose an electron and become positively charged silver ions (Ag^+). The latter bind to peptidoglycans in the bacterial cell membrane, thus leading to the destruction of the bacterial cell wall. Silver ions transported into the cell disrupt numerous cell functions by binding to proteins and interfering with energy production, enzyme function, and cell replication. Given these highly diverse effects on various target structures, development of bacterial resistance to silver is rather unlikely and clinically irrelevant [44].

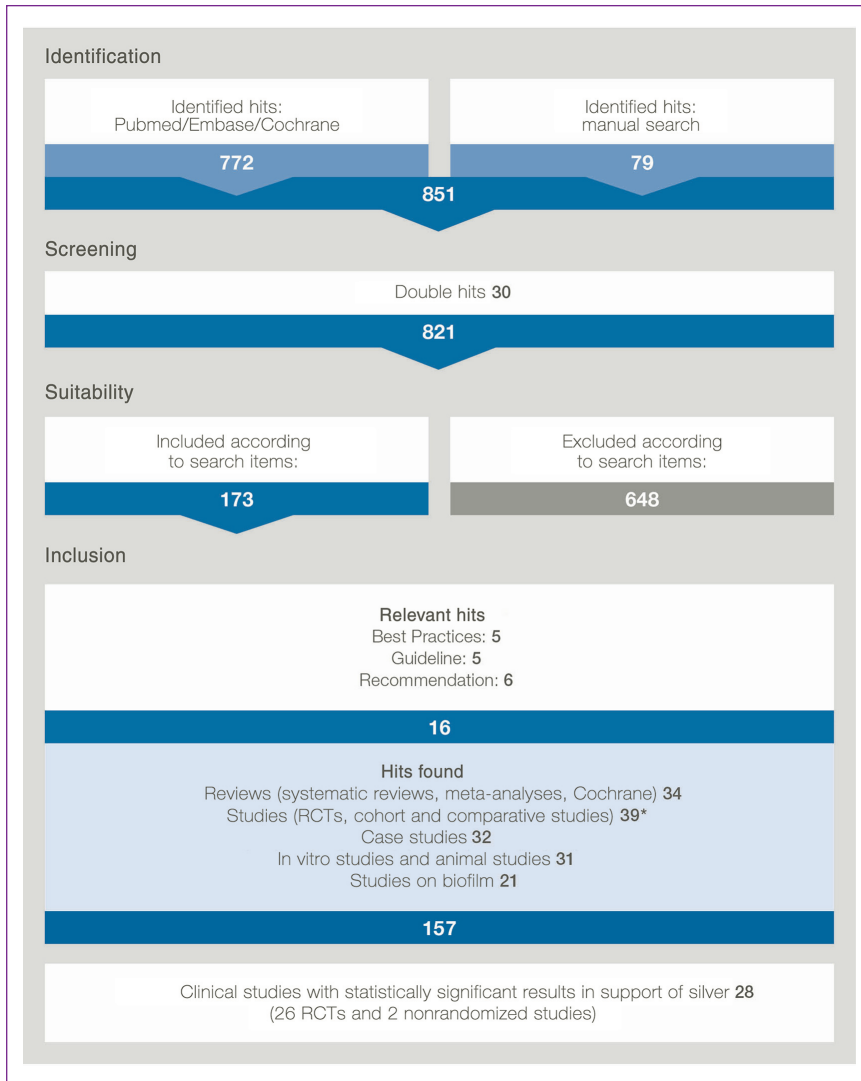


Figure 1 Diagram depicting the selection of the studies presented and analyzed herein [4].

There are at least six different preparations of silver-containing wound dressings available on the German market. These include products with activated charcoal, alginate, silicone wound contact layer, polyurethane foam, hydro-/aquafiber, and membrane dressings. In most cases, the silver contained therein only becomes active on contact with the wound exudate and is released only locally. Depending on the product and the condition of the wound, the silver concentration in the wound dressing as well as the silver ions locally available can show pronounced variability [45, 46]. However, this is likely less relevant for the clinical efficacy, given that the intended silver ion release from the wound dressing always results in a local concentration that shows at least a minimum degree of efficacy. Silver ions have been proven to be effective against many bacteria, fungi, and viruses [45]. In biofilms, silver ions reduce bacterial adhesion and destabilize the biofilm matrix, thus increasing the sensitivity of bacteria

to antibiotics [47]. Besides its antimicrobial effects, silver has been shown to have antiinflammatory effects and to promote neovascularization [45].

One of the potential side effects cited with regard to using silver in wound treatment refers to the risk of developing argyria. Following systemic absorption, silver is predominantly excreted in the feces (biliary route); some is also excreted in the urine. Unlike the systemic administration of (colloidal) silver, there have only been few cases of argyria following the topical application of silver-containing wound dressings. It should be pointed out that the extensive use of silver-containing wound dressings – for example, covering more than 70 % of the body surface – should be avoided [48]. Another, rarely described side effect are discolorations due to silver deposits in scar tissue. In particular, this cosmetically troublesome phenomenon has been observed in patients with burn injuries [49]. Continuous medical vigilance reporting,

Table 1 RCTs and comparative studies on burn injuries.

Indication and study type; number of patients	Type of endpoints and important results	Study
Burn injuries; RCT, (n = 106)	<ul style="list-style-type: none"> ▶ Higher rates of at least 50 % healing of second-degree burns (p = 0.001) ▶ More frequently, complete healing (p = 0.116) 	Adhya et al. 2014 [6]
Burn injuries; RCT, (n = 101)	<ul style="list-style-type: none"> ▶ Higher healing rates 71.7 % vs. 60.8 % ▶ Less frequent dressing changes: 2.2 vs. 12.4 ▶ Better pain reduction (p = 0.02 prior to application; p = 0.048 when in situ) ▶ Lower costs of dressing-related analgesics (p = 0.03) ▶ Better cost-effectiveness (p < 0.001) 	Silverstein et al. 2011 [7]
Burn injuries; Ila; (n = 65)	<ul style="list-style-type: none"> ▶ Lower pain score (p < 0.02) ▶ Less frequent dressing changes (p < 0.02) ▶ Less nursing time (p < 0.02) ▶ Shorter healing time (7 vs. 14 days, p < 0.02) ▶ Better cost-effectiveness 	Opasanon et al. 2010 [8]
Burn injuries; RCT, (n = 70)	<ul style="list-style-type: none"> ▶ Faster wound closure (p < 0.02) ▶ Less pain (p < 0.02) ▶ Better cost-effectiveness 	Muangman et al. 2010 [9]
Burn injuries; RCT, (n = 20)	<ul style="list-style-type: none"> ▶ Less frequent dressing changes (p = 0.01) ▶ Lower overall costs 	Silver et al. 2007 [10]
Burn injuries; RCT, (n = 84)	<ul style="list-style-type: none"> ▶ Less pain/anxiety during dressing changes (p = 0.003) ▶ Fewer dressing changes (p < 0.001) ▶ Less nursing time (p < 0.001) ▶ Fewer comedications (p = 0.002) ▶ Lower treatment costs 	Caruso et al. 2006 [11]
Burn injuries; RCT; (n = 191)	<ul style="list-style-type: none"> ▶ Shorter healing time for silver nanoparticles (Ag-NP) vs. Silver sulfadiazine (SSD) (p < 0.01) ▶ Shorter healing time for silver nanoparticles (Ag-NP) vs. Vaseline (p < 0.01) 	Chen et al. 2006 [12]
Burn injuries; RCT, (n = 98)	<ul style="list-style-type: none"> ▶ Shorter healing time (12 vs. 16 days; p = 0.005) ▶ Better elimination of bacterial colonization (p < 0.05) 	Li et al. 2006 [13]
Burn injuries; RCT, (n = 14)	<ul style="list-style-type: none"> ▶ Less pain (p < 0.0001) 	Varas et al. 2005 [14]

which manufacturers are required to carry out pursuant to the Medical Device Act, confirms that these phenomena are rarely observed in routine clinical practice.

The recommendations of scientific medical guidelines are based on clinical evidence and/or expert consensus. In Germany, the evidence for silver dressings, as for most wound dressings, has hitherto been considered insufficient despite various meta-analyses that support the use of silver:

- ▶ “This review strengthens the case for the use of silver dressings when managing infected chronic wounds. They appear more effective and are tolerated well by

patients. However, their use should be accompanied by a comprehensive wound assessment” [50].

- ▶ “This meta-analysis confirms the effectiveness of silver dressings in wound healing and improving patients’ quality of life.” “The results of this study provide objective data on the effectiveness of silver-related dressings when applied to non-healing chronic wounds” [51].
- ▶ “Studies on sustained silver-releasing dressing demonstrated a tendency for reducing the risk of infection and promoting faster healing, but the sample sizes were too small for statistical analysis or for drawing conclusions” [52].

Table 2 RCTs and comparative studies on leg ulcers.

Indication and study type; number of patients	Type of endpoints and important results	Study
Venous leg ulcer; RCT; (n = 181)	▶ Healing rate silver group 0.63 (silver) vs. 0.33 mm/week (p = 0.0021)	Senet et al. 2014 [15]
Venous leg ulcer; RCT; (n = 281)	▶ Healing rates were not significantly different when using silver dressings	Harding et al. 2012 [16]
Venous leg ulcer; RCT; (n = 42)	▶ Greater healing rate (p = 0.02) ▶ 100 % of patients treated with silver were pain-free after 8 weeks	Dimakakos et al. 2009 [17]
Venous leg ulcer; RCT; (n = 102)	▶ Greater reduction in wound size in the silver group (median 4.2 vs. 1.1 cm ²) after 4 weeks (p = 0.023) ▶ Greater reduction in wound size in the silver group (median 5.9 vs. 0.8 cm ²) after 8 weeks (p = 0.002) ▶ Higher rate of wound closure after 4 weeks (p = 0.009) ▶ Greater probability of achieving reduction in wound size > 40 %: 2.7 (p = 0.038)	Lazareth et al. 2008 [18]
Venous leg ulcer, delayed healing; IIa; (n = 619)	▶ Wound size reduced by 50 % ▶ Less fibrin coating and maceration ▶ Faster reduction in exudate ▶ Better handling ▶ Less odor and pain ▶ Less time required for dressing changes ▶ Left in place for a longer period of time (3.1 vs. 2.1 days, p < 0.05)	Münter et al. 2006 [19]
Venous/arterial leg ulcer; RCT; (n = 109)	▶ Less odor after 1 week (p < 0.02) ▶ Less exudate after 4 weeks (p < 0.01)	Romanelli et al. 2005 [20]

Table 3 RCTs on other types of chronic wounds.

Indication and study type; number of patients	Type of endpoints and important results	Study
Pressure ulcer; RCT; (n = 45)	▶ Mean healing rates and percentage reduction in PUSH score better after 8 weeks (ns) ▶ Costs estimated at 263 vs. 1.812 US dollar (p = 0.0001)	Chuangsuwanich et al. 2011 [21]
Diabetic foot syndrome; RCT; (n = 134)	▶ Mean healing time 53 days vs. 58 days (p = 0.34) ▶ Reduction in depth: 0.25 vs. 0.13 cm (p = 0.04) ▶ Ulcer improvement and less exacerbation (p = 0.058) especially in the subgroup with antibiotic use (p = 0.02)	Jude et al. 2007 [22]
Chronic wounds; RCT; (n = 82)	▶ 50 % relative reduction in the wound size in the silver group vs. 25 % in the control group (p < 0.01) ▶ Better application, easier removal, and better exudate control (p < 0.01)	Russell et al. 2005 [23]
Chronic wounds; RCT; (n = 125)	▶ Reduction of bacterial load in 85.1 % (silver) vs. 62.1 % (control) of wounds after 2 weeks (p = 0.003)	Verdú-Soriano et al. 2004 [24]

Abbr.: ns, not significant.

Table 4 RCTs and comparative study on colonized wounds and those at risk of infection.

Indication and study type; number of patients	Type of endpoints and important results	Study
Wounds (venous leg ulcer, pressure ulcer) at increased risk of infection; RCT; (n = 36)	<ul style="list-style-type: none"> ▶ Improvement in healing after 4 weeks (reduction in the wound size, p = 0.017) 	Beele et al. 2010 [25]
Critically colonized venous leg ulcer; RCT; (n = 129)	<ul style="list-style-type: none"> ▶ Greater wound reduction after 4 weeks (p = 0.034) ▶ Less odor (p = 0.04) ▶ Less exudate (p = 0.002) ▶ Less maceration (p = 0.008) 	Jørgensen et al. 2005 [26]
Colonized chronic wounds (venous leg ulcer, pressure ulcer); RCT; (n = 99)	<ul style="list-style-type: none"> ▶ Fewer bacteria and clinical infections after 4 weeks (p = 0.023) ▶ Greater wound closure rate after 4 weeks (p = 0.024) ▶ Greater reduction in wound severity score after 4 weeks (p = 0.063) ▶ Greater reduction in wound size (p = 0.034) 	Meaume et al. 2005 [27]
Critically colonized and locally infected wounds; comparative study; (n = 38)	<ul style="list-style-type: none"> ▶ PHMB- and silver-containing dressings are effective in the reduction of pain and bacteria. Critical colonization and local wound infections were reduced faster and better (p < 0.001) in the PHMB-BWD group* during the 28-day study period. 	Eberlein et al. 2012 [28]

Abbr.: BWD+PHMB, polyhexanide-containing biocellulose wound dressing.
 *Polyhexanide-containing biocellulose wound dressing (BWD) vs. the best local standard of silver dressings (Ag).

Table 5 RCTs on acute wounds.

Indication and study type; number of patients	Type of endpoints and important results	Study
NPWT (VAC); RCT; (n = 42)	<ul style="list-style-type: none"> ▶ Shorter hospitalization 7.5 vs. 19 days (p = 0.041) ▶ Better cost-effectiveness 	Siegel et al. 2014 [29]
Colorectal surgery, RCT; (n = 110)	<ul style="list-style-type: none"> ▶ Fewer postoperative infections after 30 days of follow-up (13 % vs. 33 %); (p = 0.011) 	Krieger et al. 2011 [30]
Colorectal surgery; RCT; (n = 166)	<ul style="list-style-type: none"> ▶ Less frequent bacterial contamination, 4.1 times higher in the control group 	Siah et al. 2011 [31]
Dressing for graft donor site; RCT; (n = 20)	<ul style="list-style-type: none"> ▶ Less pain on the 5th postoperative day (p = 0.02) ▶ No significant differences in healing time, infection rate, cosmetic results 	Bailey et al. 2011 [32]
Split skin graft; RCT; (n = 20)	<ul style="list-style-type: none"> ▶ Faster complete re-epithelialization 7.9 days vs. 11.2 days (p = 0.031) ▶ Less pain at rest: 0.74 vs. 0.80 (p = 0.894) ▶ Less pain during removal: 3.12 vs. 4.70 (p = 0.027) 	Lohsiriwat et al. 2009 [33]
Open surgery, traumatic wounds; RCT; (n = 67)	<ul style="list-style-type: none"> ▶ Less pain (p < 0.001) ▶ Better comfort (p ≤ 0.001) ▶ Less wound trauma on removal (p = 0.001) ▶ Better exudate management (p < 0.01) ▶ Easier to use (p ≤ 0.001) ▶ More complete healing at the end of the study: 23 % vs. 9 % (p = ns) 	Jurczak et al. 2007 [34]

Abbr.: NPWT, negative-pressure wound therapy (NPWT); VAC, V.A.C.[®] therapy; ns, not significant.

Table 6 Tabular overview of RCTs and comparative studies with statistically significant results in favor of silver.

Wound healing ¹ (n = 16)	Quality of life ² (n = 12)	Cost-effectiveness ³ (n = 8)	Reduction of bacterial load ⁴ (n = 3)	Study
x				Adhya et al. 2014 [6]
		x		Siegel et al. 2014 [29]
x				Senet et al. 2014 [15]
				Harding et al. 2012 [16]
x	x	x		Silverstein et al. 2011 [7]
		x		Chuangsuwanich et al. 2011 [21]
			x	Siah et al. 2011 [31]
	x			Bailey et al. 2011 [32]
x	x	x		Opasanon et al. 2010 [8]
x	x	x		Muangman et al. 2010 [9]
x				Beele et al. 2010 [25]
x				Dimakakos et al. 2009 [17]
x	x			Lohsiriwat et al. 2009 [33]
x				Lazareth et al. 2008 [18]
		x		Silver et al. 2007 [10]
x				Jude et al. 2007 [22]
x	x			Jurczak et al. 2007 [34]
	x	x		Caruso et al. 2006 [11]
x				Chen et al. 2006 [12]
x			x	Li et al. 2006 [13]
x	x	x		Münter et al. 2006 [19]
	x			Varas et al. 2005 [14]
	x			Jørgensen et al. 2005 [26]
x				Meaume et al. 2005 [27]
	x			Romanelli et al. 2005 [20]
x	x			Russel et al. 2005 [23]
			x	Verdu-Soriano et al. 2004 [24]

¹Wound healing: healing = complete resolution, wound closure, reduction in wound size, complete re-epithelialization.

²Quality of life: Quality of life QoL = reduction of pain score, less pain/anxiety, general comfort, less odor, less exudate, ease of application/removal.

³Efficiency: cost-effectiveness, dressing left in place for a longer period of time, lower frequency of dressing changes.

⁴Reduction of bacterial load: Qualitative and quantitative reduction of bacterial load (bioburden), reduction in infection rates.

- ▶ “Meta-analyses found strong evidence for wound healing based on wound size reduction but no evidence based on complete wound-healing or healing rates” [53].

With respect to wound management, current guidelines predominantly refer to complete wound closure as primary endpoint. This, however, does not correspond to the complexity of infected wounds and the temporally limited use of

Table 7 Tabular overview of clinical trials (RCTs, multicenter studies) with descriptive, statistically not significant results in favor of silver.

Method	Result	Study
Multicenter real-life study (n = 121)	<ul style="list-style-type: none"> ▶ NGAD* possibly plays a role in wound healing due to elimination of biofilm. ▶ Cost reduction of 30 % 	Walker et al. 2015 [35]
RCT; skin donor sites, Ag hydrofiber vs. standard (n = 70)	<ul style="list-style-type: none"> ▶ Wound pain reduced with both treatment methods 	Blome-Eberwein et al. 2010 [36]
RCT; silver vs. cadexomer iodine (n = 281)	<ul style="list-style-type: none"> ▶ Silver shows faster wound healing 	Miller et al. 2010 [37]
RCT; Ag alginate vs. alginate (n = 42)	<ul style="list-style-type: none"> ▶ No difference in local signs of infection and tolerability ▶ Difference with respect to bacteriological wound status in favor of silver 	Trial et al. 2010 [38]
Multicenter, non-comparative study in second-degree burns (n = 41)	<ul style="list-style-type: none"> ▶ No secondary infections ▶ Only one colonization with <i>Staphylococcus aureus</i> out of 121 samples 	Carsin et al. 2004 [39]

Abbr.: NGAD, next-generation antimicrobial dressing.
*NGAD = Aquacel® vs. standard protocol.

Table 8 Tabular overview of clinical trials (RCTs, clinical studies, case studies) with other assessment criteria.

Method	Result	Study
RCT (n = 315); comparison of metallic vs. ionic silver	<ul style="list-style-type: none"> ▶ No difference in wound healing and infections ▶ Differences with regard to patient comfort and dressing-specific factors 	Dickinson et al. 2015 [40]
RCT (n = 500); silver-releasing wound dressing vs. gauze in vascular surgery of the lower extremities	<ul style="list-style-type: none"> ▶ The 30-day complication rate was 30 %; postoperative wound infections (SSIs) were the most common complications ▶ In the ITT analysis, there were no complications when using the silver dressing 	Ozaki et al. 2015 [41]
Comparative study of PHMB vs. silver in critically colonized or infected wounds (n = 38)	<ul style="list-style-type: none"> ▶ After 28 days, there was a statistically significantly greater reduction in wound size ($p < 0.001$) in favor of PHMB. 	Eberlein et al. 2012 [28]
RCT (n = 110) in colorectal surgery	<ul style="list-style-type: none"> ▶ Statistically significantly fewer SSIs after 30 days of follow-up of a silver-containing wound dressing vs. gauze ($p = 0.011$) 	Krieger et al. 2011 [30]
Clinical trial	<ul style="list-style-type: none"> ▶ Only small numbers of sil-gen-resistant bacteria (MRSA and MR-CNS) were detected in wounds or the nose. These bacteria are killed by silver. 	Loh et al. 2009 [42]
RCT (n = 213) of ulcerations; VULCAN trial	<ul style="list-style-type: none"> ▶ No statistically significant effects of silver 	Michaels et al. 2009 [43]
Case study; silver-resistant <i>Enterobacter cloacae</i> isolated from a leg ulcer	<ul style="list-style-type: none"> ▶ Silver resistance of bacteria is extremely rare 	Lansdown et al. 2007 [43]

Abbr.: PHMB, polyhexanide; SSIs, surgical site infections.

antimicrobial strategies such as the application of silver-containing wound dressings. Given that the present meta-analysis therefore included other endpoints as well, we were able to find clinical evidence for silver-containing wound dressings for various indications. In some cases, this evidence was even statistically significant. In the period 2000–2015, numerous clinical studies on silver in wound care were published, including 31 RCTs. The majority of these studies provide – frequently significant – evidence for positive effects on different aspects of wound healing in various indications, Besides antimicrobial effects, these include the promotion of wound healing, improvement in quality of life, and benefits with regard to cost-effectiveness.

The present meta-analysis also included studies on very diverse types of wounds and therapeutic agents. Thus, a conclusive assessment as to the use of a particular wound dressing for a specific type of wound continues to be difficult. On the other hand, if one looks at the available evidence for a particular silver-containing foam dressing, one finds four RCTs with a total of 685 patients with venous leg ulcers. For this specific indication, this particular dressing was objectively shown to be statistically significantly superior to a non-active wound dressing with regard to various parameters such as the reduction in wound size (43.5 % vs. 26.3 %) [54].

In everyday clinical practice, the selection of a wound dressing is based on the principles of best medical practice, taking into account the best evidence available as described by Sackett et al. Thus, “evidence-based medicine is the conscientious, explicit and judicious use of current best evidence in making decisions about the care of individual patients” [55]. As a consequence of the aforementioned data, the authors of the present article have developed a clinical treatment algorithm for the use of silver dressings in wounds that are locally infected, contaminated with multiresistant pathogens (MRPs), or at risk of infection (Figure 2). It is recommended to first establish a clear indication for antimicrobial therapy. This may, for example, include local signs of infection of critically colonized or infected wounds, and explicitly comprises wounds with evidence of MRPs [56, 57]. In addition, their use can be considered for wounds at risk of infection, for instance, in immunosuppressed patients with an increased risk of infection [58].

Prior to using modern wound dressings, debridement or wound cleansing should also always be carried out if necessary [59]. Antimicrobial treatment of locally infected wounds may subsequently be conducted using silver-containing dressings [60]. Fourteen days after treatment initiation, it should be critically assessed whether the therapeutic goal has been achieved (Figure 3). If this is the case, treatment can be switched, for

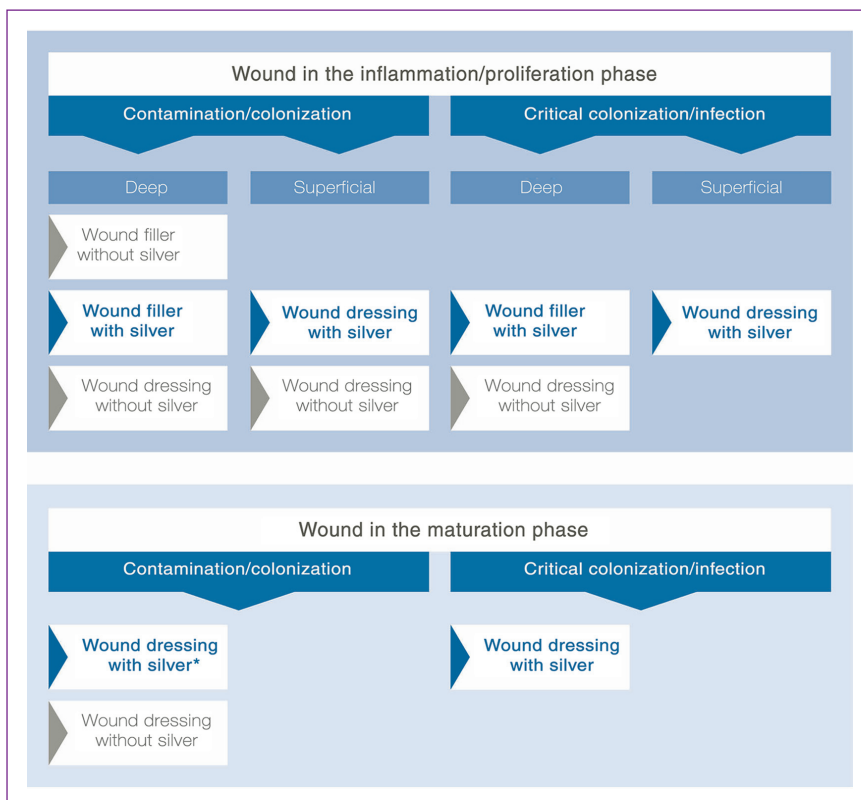


Figure 2 Treatment path for the use of silver in various phases of wound healing. *If multiresistant pathogens (MRP) are present in the wound, silver may also be used, even in case of mere contamination or colonization.

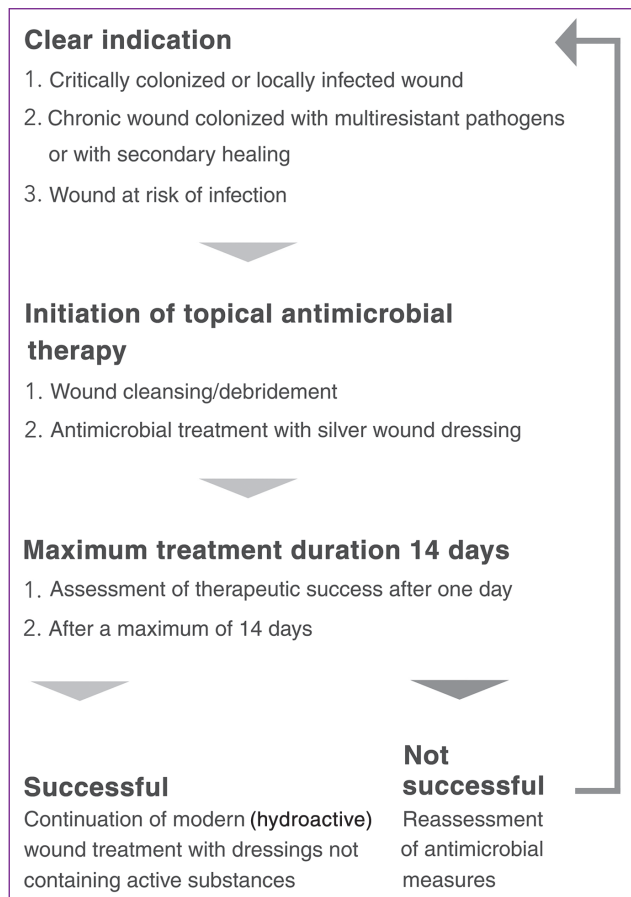


Figure 3 Algorithm for the treatment of wounds using silver-containing dressings.

instance, to a silver-free dressing; if not, the indication criteria should be re-evaluated. Depending on this assessment, wound treatment using silver may be continued or adjusted.

Conclusion for practice

The use of silver in wound management has a long tradition. As the present meta-analysis shows, the evidence base for silver is much more favorable than commonly perceived in the current scientific debate. Apart from antimicrobial effects, there is evidence suggesting that the selective and temporally limited use of silver does improve quality of life while being cost-effective. Thus, silver-containing wound dressings play a key role in modern wound management concepts.

Acknowledgments

We would also like to thank Jette Brandt from the Coloplast Corporate Knowledge Center for carrying out the literature research and ordering the original articles.

Correspondence to

Prof. Joachim Dissemond MD
Department of Dermatology, Venereology, and Allergology
University Hospital Essen
Hufelandstraße 55
45122 Essen, Germany
E-mail: joachim.dissemond@uk-essen.de

References

- 1 Wasiak J, Cleland H, Campbell F, Spinks A. Dressings for superficial and partial thickness burns. *Cochrane Database Syst Rev* 2013; 3: CD002106.
- 2 Storm-Versloot MN, Vos CG, Ubbink DT, Vermeulen H. Topical silver for preventing wound infection. *Cochrane Database Syst Rev* 2010; 3: CD006478.
- 3 Klein S, Schreml S, Dolderer J et al. Evidence-based topical management of chronic wounds according to the T.I.M.E. principle. *J Dtsch Dermatol Ges* 2013; 11: 819–29.
- 4 Dissemond J, Assenheimer B, Engels P et al. M.O.I.S.T. – ein Konzept für die Lokalthherapie chronischer Wunden. *J Dtsch Dermatol Ges* [in press].
- 5 Moher D, Liberati A, Tetzlaff J, Altman DG. The PRISMA Group. Preferred reporting items for systematic reviews and meta-analyses: The PRISMA Statement. *PLoS Med* 2009; 6: e1000097.
- 6 Adhya A, Bain J, Ray O et al. BK. Healing of burn wounds by topical treatment: A randomized controlled comparison between silver sulfadiazine and nano-crystalline silver. *J Basic Clin Pharm* 2014; 6: 29–34.
- 7 Silverstein P, Heimbach D, Meites H et al. An open, parallel, randomized, comparative, multicenter study to evaluate the cost-effectiveness, performance, tolerance, and safety of a silver-containing soft silicone foam dressing (intervention) vs. silver sulfadiazine cream. *J Burn Care Res* 2011; 32: 617–26.
- 8 Opananon S, Muangman P, Namviriyachote N. Clinical effectiveness of alginate silver dressing in outpatient management of partial thickness burns. *Int Wound J* 2010; 7: 467–71.
- 9 Muangman P, Pundee C, Opananon S, Muangman S. A prospective, randomized trial of silver containing hydrofiber dressing versus 1 % silver sulfadiazine for the treatment of partial thickness burns. *Int Wound J* 2010; 7: 271–6.
- 10 Silver GM, Robertson SW, Halerz MM et al. A silver-coated antimicrobial barrier dressing used postoperatively on meshed autografts: a dressing comparison study. *J Burn Care Res* 2007; 28: 715–9.
- 11 Caruso DM, Foster KN, Blome-Eberwein SA et al. Randomized clinical study of Hydrofiber dressing with silver or silver sulfadiazine in the management of partial-thickness burns. *J Burn Care Res* 2006; 27: 298–309.
- 12 Chen J, Han CM, Lin XW et al. Effect of silver nanoparticle dressing on second degree burn wound. *Zhonghua Wai Ke Za Zhi* 2006; 44: 50–2.
- 13 Li XL, Huang YS, Peng YZ et al. Multicenter clinical study of acticoat (nanocrystalline silver dressing) for the management

- of residual burn wounds. *Zhonghua Shao Shang Za Zhi* 2006; 22: 15–8.
- 14 Varas RP, O’Keeffe T, Namias N et al. A prospective, randomized trial of Acticoat versus silver sulfadiazine in the treatment of partial-thickness burns: which method is less painful? *J Burn Care Rehabil* 2005; 26: 344–7.
- 15 Senet P, Bause R, Jørgensen B, Fogh K. Clinical efficacy of a silver-releasing foam dressing in venous leg ulcer healing: a randomised controlled trial. *Int Wound J* 2014; 11: 649–55.
- 16 Harding K, Gottrup F, Jawień A et al. A prospective, multi-centre, randomised, open label, parallel, comparative study to evaluate effects of AQUACEL® Ag and Urgotul® Silver dressing on healing of chronic venous leg ulcers. *Int Wound J* 2012; 9: 285–94.
- 17 Dimakakos EP, Katsenis K, Kalemikerakis J et al. Infected venous leg ulcers: management with silver-releasing foam dressing. *Wounds* 2009; 21: 4–8.
- 18 Lazareth I, Meaume S, Sigal-Grinberg ML et al. The role of a silver releasing lipido-colloid contact layer in venous leg ulcers presenting inflammatory signs suggesting heavy bacterial colonization: Results of a randomized controlled study. *Wounds* 2008; 20: 158–66.
- 19 Münter KC, Beele H, Russell L et al. Effect of a sustained silver-releasing dressing on ulcers with delayed healing: the CON-TOP study. *J Wound Care* 2006; 15: 199–206.
- 20 Romanelli M, Price P. Health-related quality of life aspects after treatment with a foam dressing and a silver-containing foam dressing in chronic leg ulcers. *J Am Acad Dermatol* 2005; 52: 21.
- 21 Chuangsuwanich A, Charnsanti O, Lohsiriwat V et al. The efficacy of silver mesh dressing compared with silver sulfadiazine cream for the treatment of pressure ulcers. *J Med Assoc Thai* 2011; 94: 559–65.
- 22 Jude EB, Apelqvist J, Spraul M, Martini J. Silver Dressing Study Group. Prospective randomized controlled study of hydrofiber dressing containing ionic silver or calcium alginate dressings in non-ischaemic diabetic foot ulcers. *Diabet Med* 2007; 24: 280–8.
- 23 Russell L. The CONTOP multinational study: preliminary data from the UK arm. *Wounds UK* 2005; 1: 44–54.
- 24 Verdú Soriano J, Rueda López J, Martínez Cuervo F, Soldevilla Agreda J. Effects of an activated charcoal silver dressing on chronic wounds with no clinical signs of infection. *J Wound Care* 2004; 13: 419: 421–3.
- 25 Beele H, Meuleneire F, Nahuys M, Percival SL. A prospective randomised open label study to evaluate the potential of a new silver alginate/carboxymethylcellulose antimicrobial wound dressing to promote wound healing. *Int Wound J* 2010; 7: 262–70.
- 26 Jørgensen B, Price P, Andersen KE et al. The silver-releasing foam dressing, Contreet Foam, promotes faster healing of critically colonised venous leg ulcers: a randomised, controlled trial. *Int Wound J* 2005; 2: 64–73.
- 27 Meaume S, Vallet D, Morere MN, Téot L. Evaluation of a silver-releasing hydroalginate dressing in chronic wounds with signs of local infection. *J Wound Care* 2005; 14: 411–9.
- 28 Eberlein T, Haemmerle G, Signer M et al. Comparison of PHMB-containing dressing and silver dressings in patients with critically colonised or locally infected wounds. *J Wound Care* 2012; 21: 12–20.
- 29 Siegel HJ, Herrera DF, Gay J. Silver negative pressure dressing with vacuum-assisted closure of massive pelvic and extremity wounds. *Clin Orthop Relat Res* 2014; 472: 830–5.
- 30 Krieger BR, Davis DM, Sanchez JE et al. The use of silver nylon in preventing surgical site infections following colon and rectal surgery. *Dis Colon Rectum* 2011; 54: 1014–9.
- 31 Siah CJ, Yatim J. Efficacy of a total occlusive ionic silver-containing dressing combination in decreasing risk of surgical site infection: an RCT. *J Wound Care* 2011; 20: 561–8.
- 32 Bailey S, Carmean M, Cinat M et al. A randomized comparison study of Aquacel Ag and Glucan II as donor site dressings with regard to healing time, cosmesis, infection rate, and patient’s perceived pain: a pilot study. *J Burn Care Res* 2011; 32: 627–32.
- 33 Lohsiriwat V, Chuangsuwanich A. Comparison of the ionic silver-containing hydrofiber and paraffin gauze dressing on split-thickness skin graft donor sites. *Ann Plast Surg* 2009; 62: 421–2.
- 34 Jurczak F, Dugré T, Johnstone A et al. Aquacel Ag Surgical/Trauma Wound Study Group. Randomised clinical trial of hydrofiber dressing with silver versus povidone-iodine gauze in the management of open surgical and traumatic wounds. *Int Wound J* 2007; 4: 66–76.
- 35 Walker M, Metclaf D, Parsons D, Bowler P. A real-life clinical evaluation of a next-generation antimicrobial dressing on acute and chronic wounds. *J Wound Care* 2015; 24: 11–22.
- 36 Blome-Eberwein S, Johnson RM, Miller SF et al. Hydrofiber dressing with silver for the management of split-thickness donor sites: a randomized evaluation of two protocols of care. *Burns* 2010; 36: 665–72.
- 37 Miller CN, Newall N, Kapp SE et al. A randomized-controlled trial comparing cadexomer iodine and nanocrystalline silver on the healing of leg ulcers. *Wound Repair Regen* 2010; 18: 359–67.
- 38 Trial C, Darbas H, Lavigne JP et al. Assessment of the antimicrobial effectiveness of a new silver alginate wound dressing: a RCT. *J Wound Care* 2010; 19: 20–6.
- 39 Carsin H, Wassermann D, Pannier M et al. A silver sulphadiazine-impregnated lipodocolloid wound dressing to treat second-degree burns. *J Wound Care* 2004; 13: 145–8.
- 40 Dickinson JC, Culver CR, Baker JW. A prospective, randomized controlled trial comparing 3 dressing types following sternotomy. *Ostomy Wound Manage* 2015; 61: 42–9.
- 41 Ozaki CK, Hamdan AD, Barsheš NR et al. Prospective, randomized, multi-institutional clinical trial of a silver alginate dressing to reduce lower extremity vascular surgery wound complications. *J Vasc Surg* 2015; 61: 419–27.
- 42 Loh JV, Percival SL, Woods EJ et al. Silver resistance in MRSA isolated from wound and nasal sources in humans and animals. *Int Wound J* 2009; 6: 32–8.
- 43 Michaels JA, Campbell WB, King BM et al. A prospective randomised controlled trial and economic modelling of antimicrobial silver dressings versus non-adherent control dressings for venous leg ulcers: the VULCAN trial. *Health Technol Assess* 2009; 13: 1–114.
- 44 Landsdown AB, Williams A. Bacterial resistance to silver in wound care and medical devices. *J Wound Care* 2007; 16: 15–9.

- 45 International consensus. Appropriate use of silver dressings in wounds. An expert working group consensus. London: Wounds International, 2012, www.woundsinternational.com. Available on http://www.woundsinternational.com/media/issues/567/files/content_10381.pdf [Last accessed November 10, 2016].
- 46 <http://www.werner-sellmer.de> [Last accessed November 10, 2016].
- 47 Kostenko V, Lyczak J, Turner K, Martinuzzi R]. Impact of silver-containing wound dressings on bacterial biofilm viability and susceptibility to antibiotics during prolonged treatment. *Antimicrob Agents Chemother* 2010; 54: 5120–31.
- 48 McCague A, Joe VC. A case of argyria and acute leukopenia associated with the use of an antimicrobial soft silicone foam dressing. *J Burn Care Res* 2016; 37(5): e493-6.
- 49 Wang XQ, Chang HE, Francis R et al. Silver deposits in cutaneous burn scar tissue is a common phenomenon following application of a silver dressing. *J Cutan Pathol* 2009; 36: 788–92.
- 50 Lo SF, Hayter M, Chang CJ et al. A systematic review of silver-releasing dressings in the management of infected chronic wounds. *J Clin Nurs* 2008; 17: 1973–85.
- 51 Lo SF, Chang CJ, Hu WY et al. The effectiveness of silver-releasing dressings in the management of non-healing chronic wounds: a meta-analysis. *J Clin Nurs* 2009; 18: 716–28.
- 52 Health Quality Ontario. Management of chronic pressure ulcers: an evidence-based analysis. *Ont Health Technol Assess Ser* 2009; 9: 1–203.
- 53 Carter MJ, Tingley-Kelley K, Warriner RA. Silver treatments and silver-impregnated dressings for the healing of leg wounds and ulcers: a systematic review and meta-analysis. *J Am Acad Dermatol* 2010; 63: 668–79.
- 54 Leaper D, Münter C, Meaume S et al. The use of biatain Ag in hard-to-heal venous leg ulcers: meta-analysis of randomised controlled trials. *PLoS One* 2013; 8: e67083.
- 55 Sackett DL, Rosenberg WM, Gray JAM et al. Evidence based medicine: what it is and what it isn't. *BMJ* 1996; 312: 71.
- 56 Dissemmond J. Methicillin resistant *Staphylococcus aureus* (MRSA): Diagnostic, clinical relevance and therapy. *J Dtsch Dermatol Ges* 2009; 7: 544–51.
- 57 Schwarzkopf A, Dissemmond J. Indications and practical implementation of microbiologic diagnostics in patients with chronic wounds. *J Dtsch Dermatol Ges* 2015; 13: 203–9.
- 58 Dissemmond J, Assadian O, Gerber V et al. Classification of wounds at risk and their antimicrobial treatment with polyhexanide: a practice-oriented expert recommendation. *Skin Pharmacol Physiol* 2011; 24: 245–55.
- 59 Strohal R, Dissemmond J, Jordan O'Brien J et al. An updated overview and clarification of the principle role of debridement. *J Wound Care* 2013; 22(Suppl.): 1–52.
- 60 Dissemmond J, Augustin M, Eming SA et al. Modern wound care – practical aspects of non-interventional topical treatment of patients with chronic wounds. *J Dtsch Dermatol Ges* 2014; 12: 541–54.